Am J Clin Oncol (CCT) 25(2): 168–171, 2002. © 2002 Lippincott Williams & Wilkins, Inc., Philadelphia

Downloaded from http://journals.lww.com/amjclinicaloncology by BhDMf5ePHKav1zEoum1tQfN4a+kJLhEZgbsIHo4XMi0hCywCX1AWnYQp/IlQrHD3i3D0OdRyi7TvSFl4Cf3VC4/OAVpDDa8KKGKV0Ymy+78= on 11/21/2024

Osteoradionecrosis of the Mandible

Scientific Basis for Clinical Staging

Harry C. Schwartz, D.M.D., M.D., F.A.C.S., and A. Robert Kagan, M.D.

Osteoradionecrosis of the mandible can be a serious complication of radiotherapy for head and neck cancer. The disorder generally presents in one of several distinct clinical variations. This is probably because of a complex interaction of etiologic factors. A clinical staging system for the disorder is described. Such a system is necessary for the conduct of clinical research, and for the development and assessment of treatment regimens.
Key Words: Osteoradionecrosis—Mandible—Head and neck cancer—Radiotherapy—Side effects.

Osteoradionecrosis can be defined as a condition in which devitalized, irradiated bone becomes exposed through a wound in the overlying skin or mucosa. Such a wound must not be caused by tumor recurrence, or by tumor necrosis during radiation therapy, and it must persist without healing for 3 to 6 months. Osteoradionecrosis of the mandible can be a serious complication of radiotherapy for head and neck cancer, producing untold suffering and disability in patients who may be cured of their primary disease.

Several facts regarding osteoradionecrosis of the mandible appear to be beyond dispute[1–8]: (1) it is rare when doses of less than 6,000 cGy are used at 1,000 cGy or less per week; (2) it is more likely to occur if brachytherapy is used instead of or in addition to external beam therapy; (3) the mandible must be within the treatment volume to place it at risk; (4) the mandible is affected far more frequently than is the maxilla or the other bones of the head and neck; (5) dental extractions, surgery, or other types of trauma frequently precede the onset of osteoradionecrosis; and (6) osteoradionecrosis is a problem of impaired wound healing, not an infection like osteomyelitis, although there may be secondary infection.

A number of host factors may play a role in the onset of the disease. These include age, sex, general health, tumor stage, peripheral vascular status, tobacco and alcohol use, dental health, and compliance with preventive dental care. Treatment factors may also play a role. These may include the type and timing of surgery, the use of vascularized flaps, the use of neoadjuvant chemotherapy, and the dose, energy, fractionation, and fields of radiotherapy used. Unfortunately, none of these many factors has ever been studied in an organized prospective manner.

There is a wide spectrum in the clinical presentation of osteoradionecrosis of the mandible. In much of the literature, however, the diagnosis is made but important clinical findings are not described. Some authors have suggested staging systems.[4,5] Only that of Marx[5] is widely used. The problem with this system is that it relates to the use of and response to hyperbaric oxygen (HBO), rather than to the pathophysiology of the disease itself. The staging system of Epstein et al.[4] is an improvement, but is so focused on the presence or absence of a pathologic fracture that we have not found it useful in our patient population.

LIPPINCOTT WILLIAMS & WILKINS
Unauthorized Use Prohibited

MATERIALS AND METHODS

The authors have been involved for more than 25 years in the management of all patients treated with head and neck radiation therapy in one of the largest radiation oncology departments in the United States. All patients in whom osteoradionecrosis of the mandible subsequently developed in this time have been evaluated or managed by the authors, and all medical records have been available for review. Patterns in the degree of injury to both the bone and the overlying soft tissues emerged. Accordingly, a new clinical staging system for osteoradionecrosis of the mandible has been developed. The authors have found it to be to be very helpful for clinical assessment, management, and data collection.

Clinical Staging: Stage I Osteoradionecrosis

There is superficial involvement of the mandible only (Fig. 1). Soft-tissue ulceration is minimal. Only the exposed cortical bone is necrotic. Most of our patients seek treatment in stage I. The majority resolve with minimal conservative management. A small number progress to stage II.

Clinical Staging: Stage II Osteoradionecrosis

There is localized involvement of the mandible (Fig. 2). The exposed cortical bone and also a portion of the underlying medullary bone are necrotic. Many patients seek treatment in

From the Departments of Maxillofacial Surgery (H.C.S.) and Radiation Oncology (A.R.K.), Southern California Permanente Medical Group, and U.C.L.A., Los Angeles, California, U.S.A.

Address correspondence and reprint requests to Dr. Harry C. Schwartz, 4900 Sunset Boulevard, Los Angeles, CA 90027, U.S.A.

Downloaded from http://journals.lww.com/amjclinicaloncology by BhDMf5ePHKav1zEoum1tQfN4a+kJLhEZgbsIHo4XMi0hCywCX1AWnYQp/IlQrHD3i3D0OdRyi7TvSFl4Cf3VC4/OAVpDDa8KKGKV0Ymy+78= on 11/21/2024

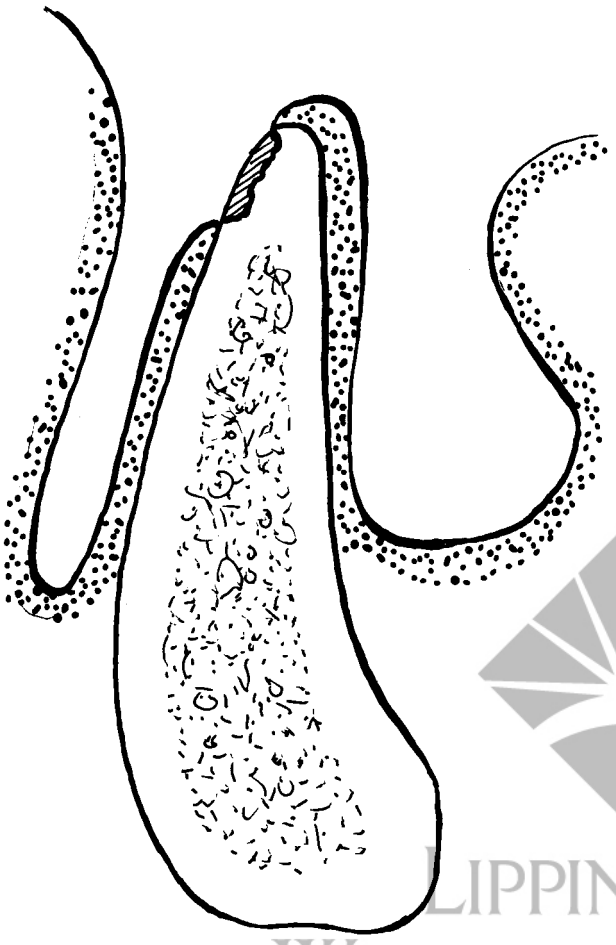

FIG. 1. Stage I, or superficial osteoradionecrosis of the mandible. Only cortical bone (shaded) exposed by a small mucosal ulcer is necrotic.

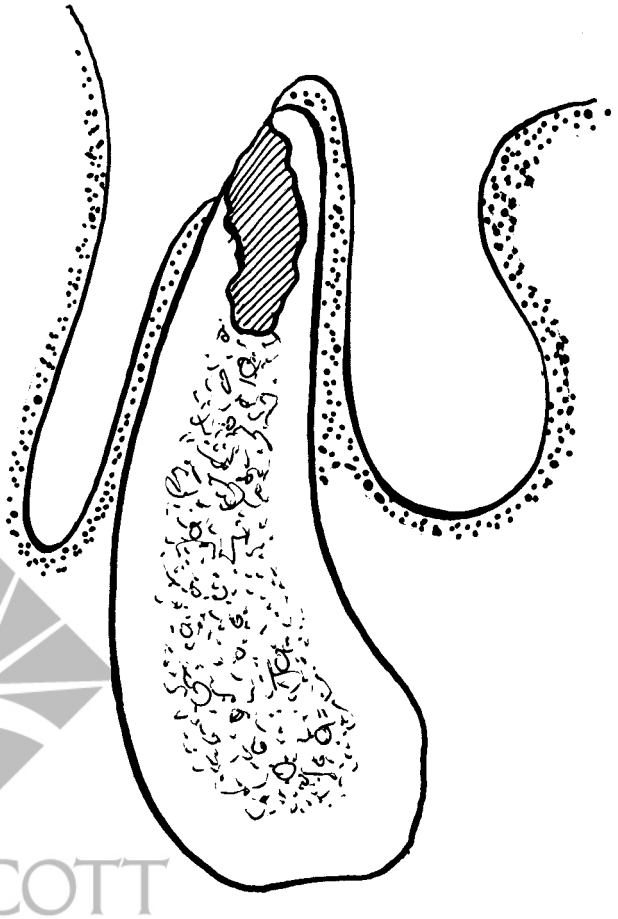

FIG. 2. Stage II, or localized osteoradionecrosis of the mandible. Both the exposed cortical bone and a portion of the underlying medullary bone (shaded) are necrotic. In division A, there is a small mucosal ulcer. In division B, there is soft-tissue necrosis.

LIPPINCOTT WILLIAMS & WILKINS

stage II, especially after a periodontal infection or a tooth extraction that has not healed. Others have progressed from stage I. The majority resolve with conservative management or minor surgical procedures. HBO has been helpful for a small number of persistent cases. Very rarely there is progression to stage III.

Division A

Soft-tissue ulceration is minimal.

Division B

There is soft-tissue necrosis, including orocutaneous fistulation (Fig. 3).

Clinical Staging: Stage III Osteoradionecrosis

There is diffuse involvement of the mandible (Fig. 4). The full thickness of a segment of bone is involved, including the lower border. Pathologic fracture may occur (Fig. 5). Even patients who have had HBO according to the Marx protocols have progressed to stage III. All require surgical intervention, including bone and/or soft-tissue replacement. Most cases were managed successfully without HBO, although HBO was helpful to control low-grade infection or bone exposure in a small number of cases.

Unauthorized Use Prohibited

Division A

Soft-tissue ulceration is minimal.

Division B

There is soft-tissue necrosis, including orocutaneous fistulation (Fig. 6).

DISCUSSION

It would be very helpful to know which of our patients are most at risk to develop osteoradionecrosis of the mandible, and to develop preventive strategies. It is clearly desirable to develop evidence-based treatment guidelines and outcome predictors for this disorder. There have been many studies of patients with osteoradionecrosis. In most, the actual clinical presentation is never further defined. A universally accepted system of clinical terminology must be established if meaningful scientific studies are to be carried out.

FIG. 3. Soft-tissue necrosis overlying the lingual alveolus in a case of localized osteoradionecrosis. The patient had received brachytherapy to the tongue and floor of mouth. This case was classified stage II-B, because the lower border of the mandible was not necrotic.

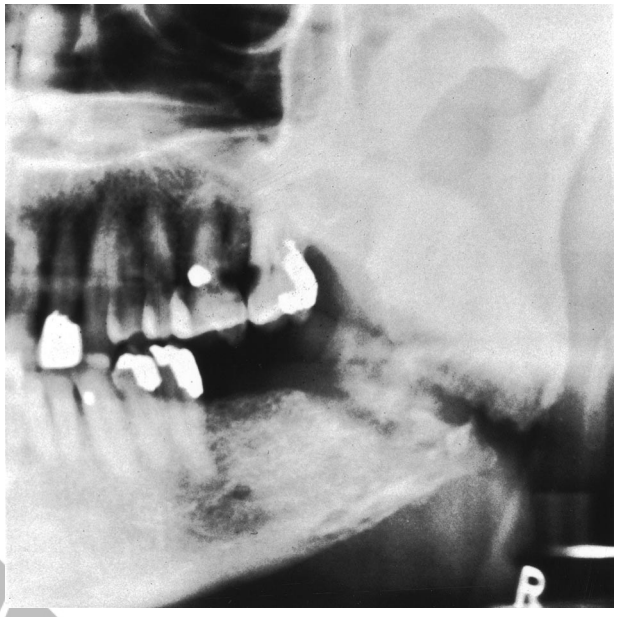

FIG. 5. Pathologic stress fracture in a case of diffuse osteoradionecrosis.

The complex interaction of many host factors and treatment parameters probably accounts for the variety of clinical presentations of osteoradionecrosis of the mandible. The various presentations can behave differently, with distinct natural histories and responses to therapy. The staging system we have outlined is descriptive of these clinical presentations, and facilitates their study. Marx's staging system[5] is useless for patients who are not treated with HBO (the great majority of patients, in our experience). Although HBO has been widely used in osteoradionecrosis of the mandible,[5,9,10] the treatment is empirical. All reports of its efficacy are anecdotal. It has never been evaluated in a prospective, controlled clinical trial. Our own clinical experience, as well as the reports of others, indicates that most cases can be managed successfully without HBO.[3,4,11–15] In view of the cost of this form of therapy, it would be highly desirable to predict which of our patients might benefit from HBO,

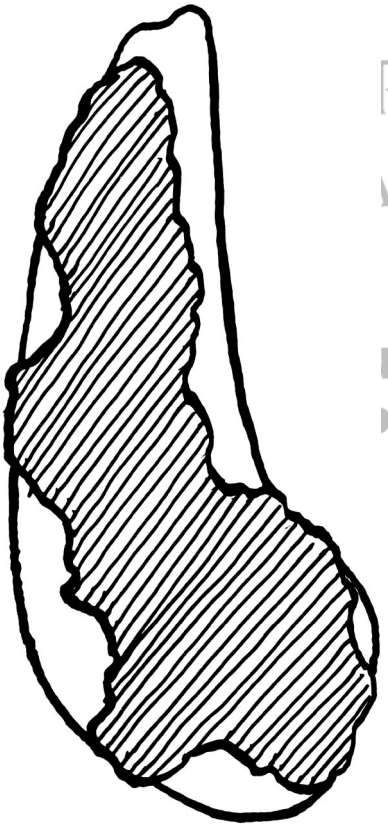

FIG. 4. Stage III, or diffuse osteoradionecrosis of the mandible. The full thickness of the mandible (shaded) is necrotic.

FIG. 6. Orocutaneous fistula in a case of diffuse osteoradionecrosis (stage III-B).

Downloaded from http://journals.lww.com/amjclinicaloncology by BhDMf5ePHKav1zEoum1tQfN4a+kJLhEZgbsIHo4XMi0hCywCX1AWnYQp/IlQrHD3i3D0OdRyi7TvSFl4Cf3VC4/OAVpDDa8KKGKV0Ymy+78= on 11/21/2024

PPINCOTT
AMS & WILKINS
uthorized Use
Prohibited

and which will do well without it. Although it can be very tempting to impose our enthusiasm for new therapies on our patients, unbiased scientific studies are essential before treatment protocols can be recommended without qualification.

CONCLUSION

Osteoradionecrosis of the mandible after radiotherapy of the head and neck, like other complications of necessary medical treatments, can be disabling to our patients and burdensome to our medical resources. We can no longer discuss this disorder in generic terms, because great differences among our patients are so apparent. We should no longer treat it in an unscientific manner. Unambiguous, universally understood clinical terminology must be adopted if the problem is to be properly studied. To this end, a clinical staging system has been developed. It is hoped that careful clinical research will provide us with a better understanding of the disease, will enable us to better predict those patients at risk, and will permit us to provide them with the individualized treatment that is best suited to their disease status.

REFERENCES

1. Beumer J, Harrison R, Sanders B, et al. Preradiation dental extractions and the incidence of bone necrosis. *Head Neck Surg* 1983; 5:514–521.
2. Beumer J, Harrison R, Sanders B, et al. Postradiation dental extractions: a review of the literature and a report of 72 episodes. *Head Neck Surg* 1983;6:581–586.
3. Beumer J, Harrison R, Sanders B, et al. Osteoradionecrosis: predisposing factors and outcomes of therapy. *Head Neck Surg* 1984;6:819–827.
4. Epstein JB, Wong FLW, Stevenson-Moore P. Osteoradionecrosis: clinical experience and a proposal for classification. *J Oral Maxillofac Surg* 1987;45:104–110.
5. Marx RE. A new concept in the treatment of osteoradionecrosis. *J Oral Maxillofac Surg* 1983;41:351–357.
6. Morrish RB, Chan E, Silverman S, et al. Osteoradionecrosis in patients irradiated for head and neck carcinoma. *Cancer* 1981;47: 1980–1983.
7. Murray CG, Herson J, Daly TE, et al. Radiation necrosis of the mandible: a 10 year study. Part I. Factors influencing the onset of necrosis. *Int J Radiat Oncol Biol Phys* 1980;6:543–548.
8. Murray CG, Herson J, Daly TE, et al. Radiation necrosis of the mandible: a 10 year study. Part II. Dental factors: onset, duration and management of necrosis. *Int J Radiat Oncol Biol Phys* 1980; 6:549–553.
9. Hart GB, Mainous EG. The treatment of radiation necrosis with hyperbaric oxygen (OHP). *Cancer* 1976;37:2580–2585.
10. Mansfield MJ, Sanders DW, Heinbach RD, et al. Hyperbaric oxygen as an adjunct in the treatment of osteoradionecrosis of the mandible. *J Oral Maxillofac Surg* 1981;39:585–589.
11. Daly TE, Drane JB. Osteoradionecrosis of jaws. *Cancer Bull* 1972;24:86–92.
12. Harris M. The conservative management of osteoradionecrosis of the mandible with ultrasound therapy. *Br J Oral Maxillofac Surg* 1992;30:313–318.
13. Marciani R, Ownby H. Osteoradionecrosis of the jaws. *J Oral Maxillofac Surg* 1986;44:218–223.
14. Schwartz HC. Treatment of osteoradionecrosis with measures other than hyperbaric oxygen. *Proceedings of the First International Congress on Maxillofacial Prosthetics.* New York: Memorial Sloan-Kettering Cancer Center; 1995:192–198.
15. Wong JK, Wood RE, McLean M. Conservative management of osteoradionecrosis. *Oral Surg* 1997;84:16–21.

Downloaded from http://journals.lww.com/amjclinicaloncology by BhDMf5ePHKav1zEoum1tQfN4a+kJLhEZgbsIHo4XMi0hCywCX1AWnYQp/IlQrHD3i3D0OdRyi7TvSFl4Cf3VC4/OAVpDDa8KKGKV0Ymy+78= on 11/21/2024

LIPPINCOTT WILLIAMS & WILKINS

Unauthorized Use Prohibited